

## Oral Medicine Feature Article

Steven M. Hayes, DDS, FAGD

### Abstract

Lichen planus is a disease that involves the skin and mucous membranes. It is characterized by unique eruptions. The cause of this disease is unknown, but has been linked to emotional stress, and has also been attributed to viral infections. A case is described of a successful treatment of lichen planus.

Received: April 17, 1998

Accepted: September 24, 1998

## Lichen planus—Report of successful treatment with aloe vera

Lichen planus is a disease that involves the skin and mucous membranes. It is characterized by the unique eruptions of symmetrically distributed, flat-topped, polyhedral, violaceous or red papules, which are scaly and pruritic.<sup>1</sup> These lesions usually involve flexural surfaces and mucous membranes, either alone or in groups.<sup>2</sup>

Almost all patients with lichen planus have oral lesions, which may precede or follow the appearance of lesions on the skin. However, lesions may be limited to the oral cavity. Clinically, the oral lesions appear as white or yellowish-white lines that are arranged in a lace-like pattern. The cause of this disease is unknown, but has been linked to emotional stress, and has also been attributed to viral infections. The average duration of the disease is about 45 months.

The treatment is usually symptomatic, including topical, intralesional, and systemic corticosteroids, depending on the severity of the symptoms. Although topical steroids have some degree of success in relieving the itching, systemic steroids must be used to make the patient comfortable in most instances. However, extreme caution should be taken when using systemic steroids because of the serious side effects encountered and the possibility of adrenal crisis.

Because of these side effects, the possibility of prolonged treatment with steroids, and the fact that the disease process could still last for years, an alternative therapy is desirable. Treatment with aloe-based products has been proposed and used because the Food and Drug Administration has considered the gel of the aloe vera plant safe for

consumption. Some studies show that aloe-based products were safe to use on skin and that they were able to help promote healing.<sup>3</sup> The following case report documents the use of aloe-based products for treating lichen planus.

### Case report

A dermatologist and a medical clinic diagnosed a 52-year-old woman as having psoriasis. Their treatment consisted of Lidex cream (Medicis—The Dermatology Company, Phoenix, AZ; number not available) where there was fungal involvement with the skin lesions, and a topical application of cortisone cream. When the patient was seen three months later for her regular cleaning and check-up appointment, intraoral lesions were noted pathognomonic with the pattern of lichen planus, during the clinical examination (Fig. 1).

In addition, the patient pointed out the skin lesions on the palms of her hands (Fig. 2). The patient stated that the prescriptions of Lidex cream and cortisone had not worked for her and that her condition had worsened. She still had the itching and burning sensations on her hands, and she stated that her lips also had these symptoms. The clinical impression, based on examination of the intraoral soft tissues which were characterized by lichen planus-type lesions, was that the condition was not psoriasis. As for the lesions on her hands, these were believed to be another sign of the disease process.

The proposed therapy involved drinking 2.0 oz of stabilized aloe vera juice (Carrington Laboratories, Dallas, TX; 800/527-5216) daily for three months. After this period, the progress of this therapy

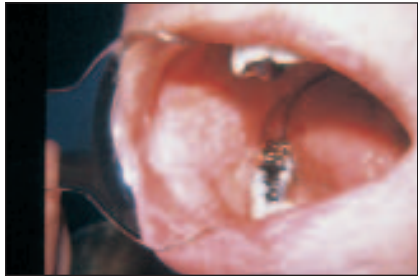

Fig. 1. Initial examination of the mouth.

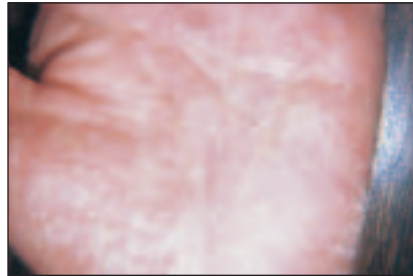


Fig. 2. Initial examination of the hand.

Table. Constituents of aloe vera gel.

<b>The principal ingredients in addition to water are:</b>	<b>Amino acids:</b>	<b>Monosaccharides and polysaccharides:</b>
Alain	Lysine	Glucose
Barbaloin	Histidine	Mannose
Etheral oil	Arginine	Uronic acid
Cinnamic acid	Hydroxyproline	
Isobarbaloin	Aspartic acid	
Emodin	Threonine	<b>Vitamins:</b>
Emoding lucosides of d-Arabinose	Serine	Vitamin B <sub>1</sub>
Ester of cinnamic acid	Glutamic acid	Niacinamide
Resitannol	Proline	Vitamin B <sub>2</sub>
	Glycine	Vitamin B <sub>6</sub>
	Alanine	Vitamin C
	Valine	Choline
<b>Inorganic ingredients:</b>	one-half cystine	
Calcium	Methione	
Potassium	Isoleucine	
Chlorine	Leucine	
	Tyrosine	
	Phenylalanine	

would be evaluated. The patient received a complete explanation of the safety of the suggested treatment, and was told of success with aloe vera in dealing with other dental problems.<sup>4,5</sup> In addition, she was told that aloe vera had been used for over 2000 years without any reported adverse reaction.<sup>6</sup>

It should be noted here that two recent studies have supported such claims. Johnson et al. demonstrated the safety of treating human skin fibroblasts with aloe-based gel (Carrington Dermal Wound Gel, or CDWG). CDWG, Betadine, Granulex, Hibiclens, (povidone-iodine; chlorhexidine gluconate; and a combination of trypsin, balsam peru, castor oil,

and an emulsifier), and hydrogen peroxide were each applied to human fibroblast cells. After 15 minutes of treatment, CDWG killed no more than 5% of the cells. In the same time, each of the other agents killed 100% of the cells.<sup>3</sup>

In another study, Rodriguez-Bigas et al. studied the healing effects of various agents on thermal burns. Animals were subjected to controlled burns and then treated with either CDWG, salicylic acid, silver sulfadiazine cream (Silvadine), or plain gauze dressing (control group). The average time required for complete healing of these full-thickness wounds was 50 days in the control group, 45 days in the salicylic acid

## Benefits of aloe vera

Peter G. Sturm, DDS, MAGD  
Associate Editor

The fresh gel from the aloe vera plant has been used internally and externally since at least 400 B.C. This tropical plant, a member of the succulent lily family, has been examined repeatedly and studies conclude this most durable plant has amazing qualities.

Aloe vera is seen in carvings on temple walls dating to the Fourth Millennium B.C.<sup>1</sup> The Egyptians referred to this plant as "The Plant of Immortality." It has been suggested that the secret of ancient embalming may lie with the plant whose drawings adorn the sides of sarcophagi. The first documented indication of the broad spectrum uses attributed to the aloe vera plant are found in first-century records of the Greek physician Dioscorides and the Roman naturalist Pliny.

The benefits of aloe vera have been confirmed by research in medical schools, independent laboratories, and by large numbers of clinical cases. Aloe vera gel 1) anesthetizes tissue, 2) is bactericidal, 3) is virucidal, 4) is fungicidal, 5) is hemostatic, 6) is an antipyretic, 7) is an anti-inflammatory, 8) is an antipruritic, 9) is a capillary dilator, 10) is an enhancer of normal cell proliferation and epithelialization, and 11) is a tissue moisturizer.<sup>2-9</sup>

In recent years, a method of stabilizing the aloe's gel was perfected. This permitted

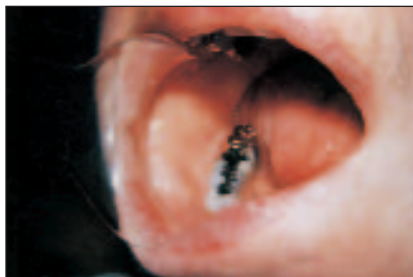products to be created which duplicated the effects available directly from a fresh plant. Until then, the limited few hours of freshness of a leaf was the best we had; now, for the first time, the special properties could be maintained to permit new uses and extended access.

Aloe products have been found to have specific benefits for dental needs. Lips can be treated with aloe to aid angular cheilitis, dry lips, and even herpes. Using a liquid aloe is effective in reducing discomfort following oral or periodontal surgery, ulcers, sore throats, and other ills. Using a thickened, cream aloe product inside an immediate denture reduces bleeding time as well as reducing swelling and inflammation. A jelly version is useful when placed within an extraction socket to accelerate the entire healing response.

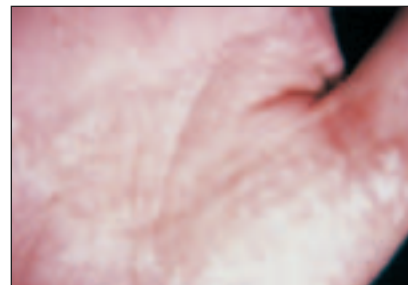
The liquid, or gel, version is dramatic when a gauze soaked in it is placed over an extraction site immediately after a tooth is removed. Post-operative pain, swelling, and bleeding are significantly reduced. The gel can also be used over sites of periodontal surgery or other surgery.

**Is all aloe the same?**

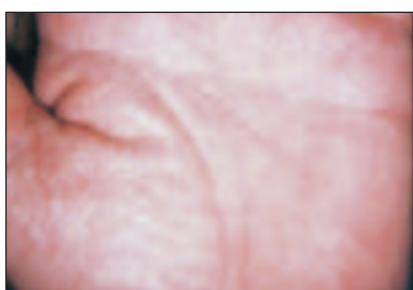The meat or gel of an aloe plant oxidizes when exposed to oxygen for several hours (similar to what happens to a sliced apple). Manufacturers must process the plant in a timely manner. Whole leaf aloe products include the outer part of the leaf which has no nutritional value and thus acts as a filler and should be avoided. To function at its optimum, aloe must be stabilized without chemicals or heat. *Aloe barbadensis miller* is the most potent and nutritious species of aloe vera. Many products available in today's market are



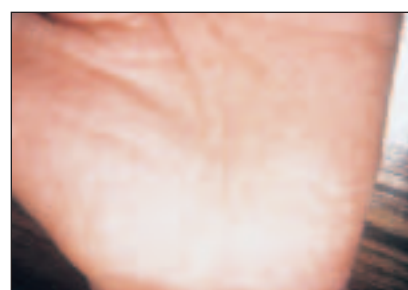**Fig. 3. One month application and progress of the mouth.**



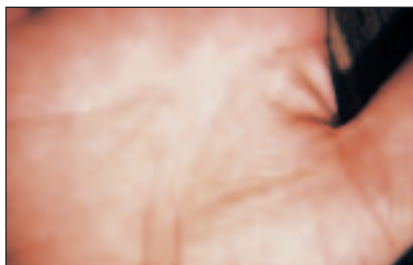
**Fig. 4. One month application and progress of the hand.**



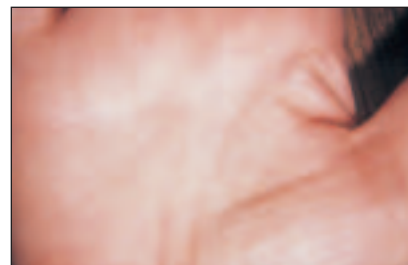
**Fig. 5. Two months application and progress of the hand.**



**Fig. 6. Three months application and progress of the hand.**



**Fig. 7. Six months application and progress of the hand, showing some scar tissue.**



**Fig. 8. Seven months application and progress of the hand, barely revealing scar tissue.**

group, and 47 days in the Silvadine group. An average of only 30 days was required for complete healing in CDWG-treated animals.<sup>7</sup>

The gel of this plant contains all the essential amino acids, as well as numerous monosaccharide and polysaccharides; vitamins B<sub>1</sub>, B<sub>2</sub>, B<sub>6</sub>, and C; niacinamide and choline; several inorganic ingredients; enzymes including acid phosphatase, alkaline phosphatase, amylase, lactic dehydrogenase, lipase, SGOT, and SGPT; and numerous organic compounds.<sup>5</sup>

It was believed that the patient might be deficient in some of these components, thereby contributing to her inability to cope with certain stress factors. These

stress factors are somewhat linked to complex interrelated biochemical reactions which are directly dependent upon the availability of many of the components contained in the gel of the aloe-vera plant.

In addition, it was hoped that the pharmacological properties of the aloe vera gel would improve the condition. That is, if the disease is a result of a virus, then the virucidal properties of the gel over a period of time would reverse the condition; the anti-inflammatory properties of the gel would help the inflammatory response; and the anti-pruritic properties would help relieve the itching and burning sensations.<sup>4,8</sup>

The patient began drinking 2.0 oz of stabilized aloe vera juice daily starting the day of her first appointment. She was given aloe vera lip balm, which is a preparation to soothe burning and itching lips, and aloe creme to help with the itching of her hands. Aloe creme is an aloe vera-based creme containing 75% stabilized aloe vera.

The patient returned after two weeks for evaluation. Some of the striations in the mouth were disappearing; a slight decrease in edema in the palms of the hands was noted. The patient also reported that the aloe vera lip balm and the aloe creme helped to relieve the itching and burning sensations better than anything she had tried previously.

The patient returned again two weeks later. The oral lesions had disappeared (Fig. 3) and her hands were beginning to show slight signs of improvement (Fig. 4). The lesions on her hands were probably another systemic manifestation of lichen planus and by continuing with the aloe vera program, these lesions might resolve. It was worth trying.

From this point on, the patient returned to the office for evaluation at regular one month intervals. And even though the oral lesions cleared up in one month, the systemic lesions were more difficult to bring under control. The continued improvement in her hands is shown after two months (Fig. 5) and after three months (Fig. 6).

At this point the patient, being quite restless with the slowness of the response in her hands, stopped taking the aloe vera juice, and went to seek treatment for psoriasis at a dermatology clinic, where they started her on UV light treatment. However, owing to frustration and the lack of progress in their treatment, the medical clinic suggested and in fact performed a biopsy of the skin lesions; the diagnosis was lichen planus. The patient returned to the dentist a few weeks later because the only result she could observe was that

her skin was getting tanner but her hands were getting worse.

The patient decided to continue the original course of treatment which had already cleared up the oral lesions and slowly began to have a beneficial effect on her hands. She was started back on the aloe vera juice; however, this time the dose was doubled to 4.0 oz per day. When the patient returned in three weeks, now six months after starting treatment, she was very happy and delighted to show that the skin lesions were disappearing (Fig. 7). In addition, her itching and burning sensations were subsiding. Her only complaint was that her hands felt dry. A few weeks later her hands began to take on a more natural texture and softness (Fig. 8), seven months after the original diagnosis of lichen planus was made and aloe vera treatment initiated. The patient noted that all of her symptoms were gone and that her hands felt soft and smooth once again.

### Conclusion

A case of oral lichen planus with severe systemic involvement was treated successfully using a very conservative and safe method of treatment—the consumption of and the topical application of stabilized aloe vera. It must be noted that no other dietary supplement, antimicrobial, or steroid agent was used. The oral lesions cleared up very quickly within four weeks. However, the systemic lesions took much longer, owing in part to the fact that the patient sought an alternate source of treatment while discontinuing the suggested therapy. This interrupted the gradual improvement she was getting using aloe vera, and ultimately increased the length of treatment. However, complete success was still achieved.

Although there are very few clinical reports in the literature, it is hoped that other health practitioners will consider using aloe vera when treating their patients with lichen planus or any other dental problem, and, if successful,

watered down or improperly stabilized, creating a product ranging from useless to minimally better than water itself.

### Too good to be true?

Many people learning about aloe tend to doubt it can be capable of all that is attributed to it. But it is important to study its history and evaluate the product for yourself. Utilizing the proper aloe product can become exciting to watch. Find a source of this aloe vera and apply it to your sunburn or to a blister. Watch it perform in its unique way.

### The true secret

After many years of using stabilized as well as fresh aloe, certain subtle observations have been made. These will be shared for the first time now. There is a direct relationship between the time post-trauma before application and the success of aloe's use. If you get a cut and wait hours to apply aloe, the healing response will not be uniquely special. Put it over a wound immediately after it occurs and aloe performs as it should. Do NOT apply to puncture wounds.

One of aloe's characteristics is its ability to penetrate tissue. This brings the medicament to the area needing it; however, it can carry puncture contaminants deeper and is, therefore, contraindicated in such instances (for example, stepping on a nail; not a tooth socket). And, finally, apply small amounts at frequent intervals. Let the aloe soak into the tissue. The exception to this is when an immediate denture is lined with aloe creme or a socket is packed with the jelly version. Good luck.

### References

1. Coats BC. The silent healer—A modern study of aloe vera. Bill C. Coats. Garland, Texas. 1979.

2. Lorenzetti L, Salisbury R, Beal JN, Baldwin JN. Bacteriostatic properties of aloe vera. *Jour Amer Pharm Sci* 1964;53:1287.

3. Hayes SM. Tic doulereaux—A report of successful treatment of a case with aloe vera. *Gen Dent* 1984;32:441-442.

4. Zimmermann ER. Germicidal properties of aloe vera against three bacterial organisms, one fungal, and two viral agents. (Thesis submitted to Baylor University College of Dentistry, Department of Microbiology.) Dallas, Texas. 1969.

5. Zawahry EM, Hegazy RM, Helal M. Uses of aloe in treating leg ulcers and dermatosis. *Int Jour Derm* 1973;12:68-73.

6. Brasher J, Zimmerman E, Collings CK. Effects of prednisolone, indomethacin, and aloe vera gel on tissue culture cells. *Oral Surg Oral Med Oral Pathol* 1969;27:122-128.

7. Rodriguez-Bigas M, Cruz N, Suarez A. Comparative evaluation of aloe vera in the management of burn wounds in guinea pigs. *Jour Plast Reconstr Surg* 1988;81:386-389.

8. Johnson AR, White AC, McAnally B. Comparison of common topical agents for wound treatment: cytotoxicity for human fibroblasts in culture. *Wounds* 1989;1:186.

9. Rowe T, Parks LM, Lovell BK. Further observations on the use of aloe vera leaf in the treatment of third degree x-ray reactions. *J Am Pharm Assoc* 1941;62: 269-270.

report their findings. Only in this manner will the true potential of aloe vera in treating this dreadful disease be known.

#### Author information

Dr. Hayes practices restorative and prosthetic dentistry in Pleasant Hill, CA. He received his Fellowship in the Academy of General Dentistry in 1977 and has been using aloe vera-based products in his practice for over 15 years with great success.

Address correspondence to: Steven M. Hayes, DDS, FAGD, 1952 Contra Costa Blvd., Pleasant Hill, CA 94523.

#### References

1. Bhaskar SN. Synopsis of oral pathology, ed. 2. St. Louis: C.V. Mosby; 1965:301-304.

2. Osol A, Roverton P, Altschule M, eds. The United States dispensatory, ed. 26. Philadelphia: J.B. Lippincott; 1967:42-43.

3. Johnson AR, White AC, McAnally B. Comparison of common topical agents for wound treatment: cytotoxicity for human fibroblasts in culture. *Wounds* 1989;1:186.

4. Hayes SM. Tic doulereaux—A report of successful treatment of a case with aloe vera. *Gen Dent* 1984; 32:441-442.

5. Sturm PG, Hayes SM. Aloe vera in dentistry. *The Journal of the Bergen County Dental Society* 1984;11-14.

6. Coats BC. The silent healer—A modern study of aloe vera. Bill C. Coats. Garland, Texas. 1979.

7. Rodriguez-Bigas M, Cruz N, Suarez A. Comparative evaluation of aloe vera in the management of burn wounds in guinea pigs. *Jour Plast Reconstr Surg* 1988;81:386-389.

8. Zimmermann ER. Germicidal properties of aloe vera against three bacterial organisms, one fungal, and two viral agents. (Thesis submitted to Baylor University College of Dentistry, Department of Microbiology.) Dallas, Texas. 1969.

9. Barnes TC. The healing action of extracts of aloe vera leaf on abrasions of human skin. *Amer Jour Bot* 1947;34:597.

10. Blitz J, Smith JW, Gerard JR. Peptic ulcer therapy by aloe vera gel. *JAOA* 1973;62.

11. Bovik EG. Aloe vera—Panacea or old wives' tale? *Tex Dent Jour* 1966; 13-16.

12. Brasher J, Zimmerman E, Collings CK. Effects of prednisolone, indomethacin, and aloe vera gel on tissue culture cells. *Oral Surg Oral Med Oral Pathol* 1969;27:122-128.

13. Brown J. Use of aloe vera on radiation burns. *Cancer Jour Clin* 1963;14:14-15.

14. Collins CE. Avagel as a therapeutic agent of roentgen and radium burns. *Radiological Rev Chi Med Rec* 1935;57:137-138.

15. Crewe JE. Aloe treatment for aplonar excema, pruritus vulva, external ulcers, poison ivy, and burns. *Minn Jour Med* 1937:670-673.

16. Crewe JE. External use of aloes. *Minn Jour Med* 1937;20:538-539.

17. Danhof IE, McAnally BH. Stabilized aloe vera: effect on human skin cells. *Drug Cosmet Ind* 1983;133:52.

18. Lorenzetti L, Salisbury R, Beal JN, Baldwin JN. Bacteriostatic properties of aloe vera. *Jour Amer Pharm Sci* 1964;53:1287.

19. Mandeville F. Aloe vera in the treatment of radiation ulcers of mucous membranes. *J Radiol* 1939;32: 598-599.

20. Payne, JM. Tissue response to aloe vera gel following periodontal therapy. (Thesis submitted to faculty of Baylor University in partial fulfillment of the requirements for the degree of Master of Science.) Dallas, Texas. 1970.

21. Rose L, Kaye D. *Intern Med Dent* 1983:938-939.

22. Rowe T, Parks LM, Lovell BK. Further observations on the use of aloe vera leaf in the treatment of third degree x-ray reactions. *J Am Pharm Assoc* 1941;62: 269-270.

23. Wright CS. Aloe vera in the treatment of roentgen ulcers and telangiectasis. *JAMA* 1936;106:1363-1364.

24. Zawahry EM, Hegazy RM, Helal M. Uses of aloe in treating leg ulcers and dermatosis. *Int Jour Derm* 1973;12: 68-73.